

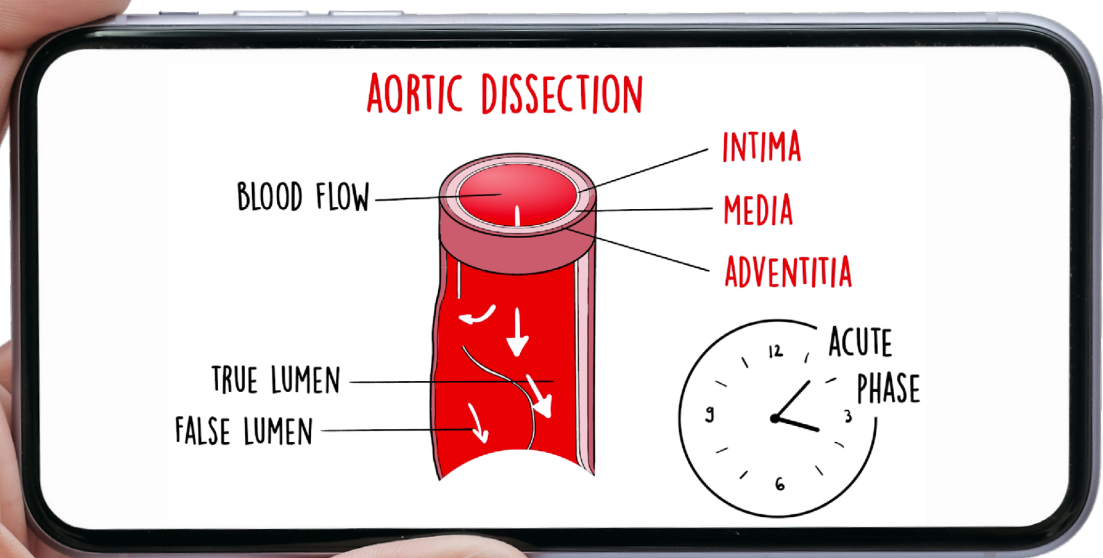
COULD IT BE **AORTIC** DISSECTION?

CONSIDER IT

DIAGNOSE IT

EXCLUDE IT

Take your 3 minute masterclass
Created for you by experts



SCAN ME
bit.ly/Could-it-be-AD